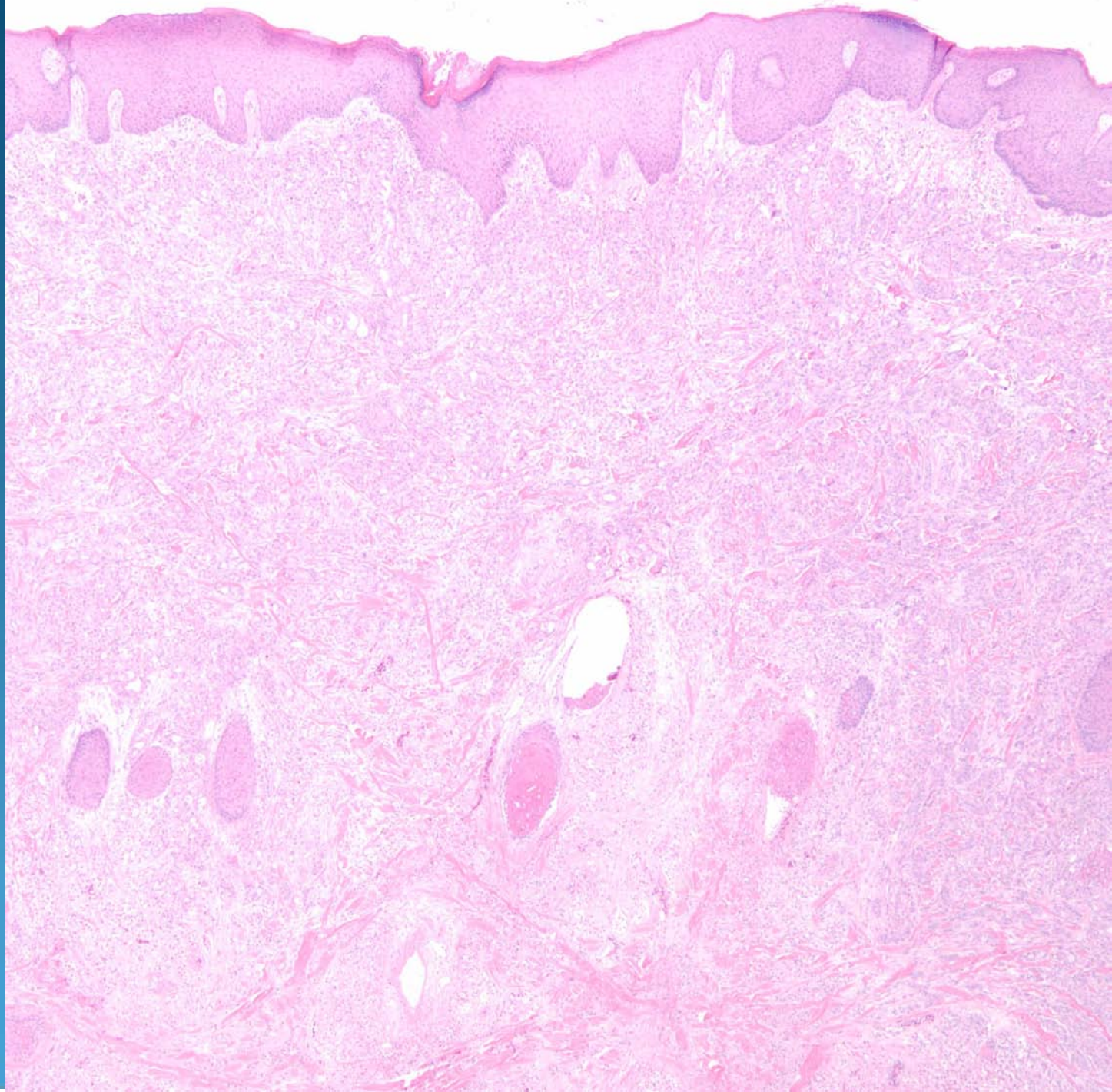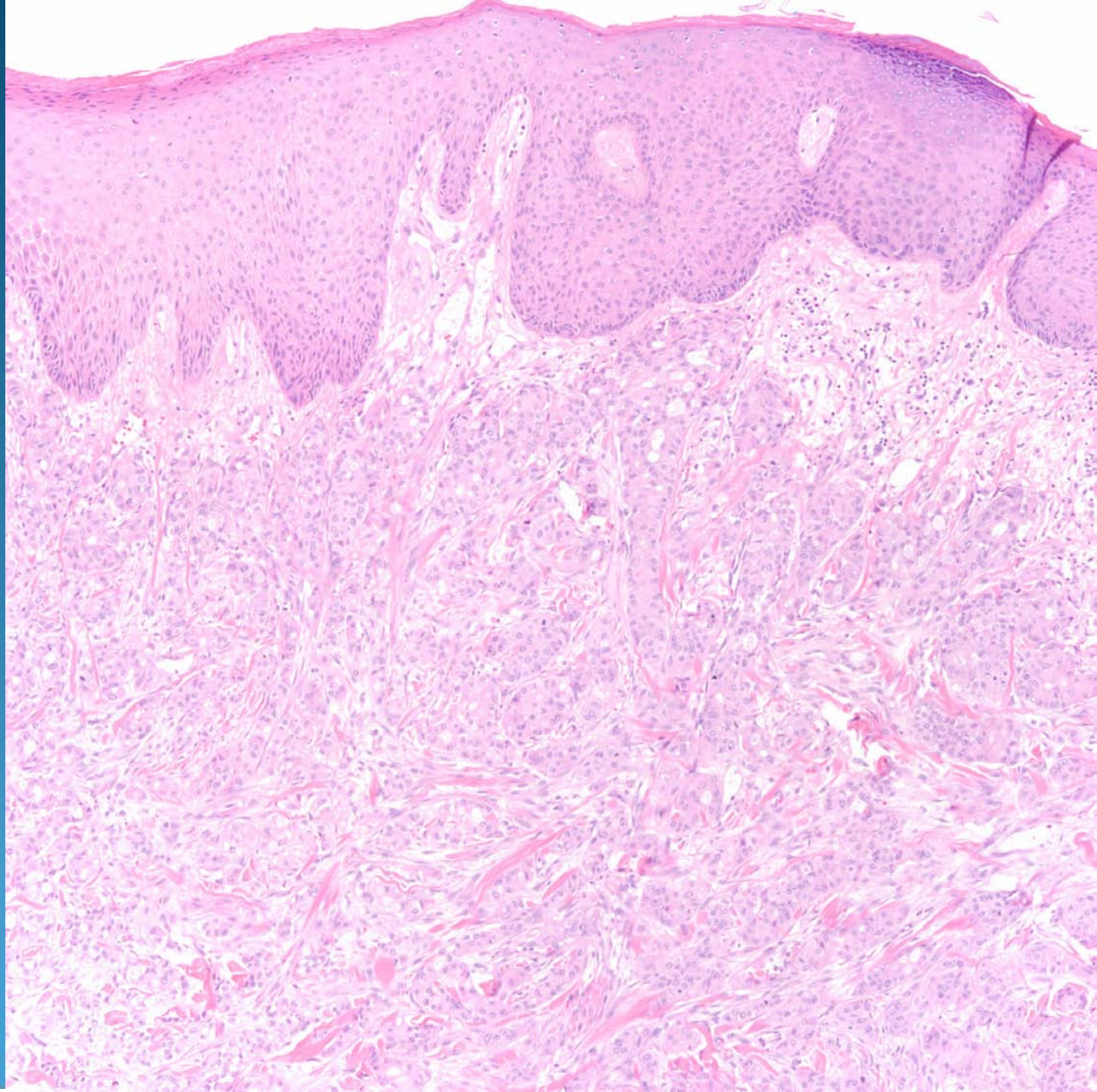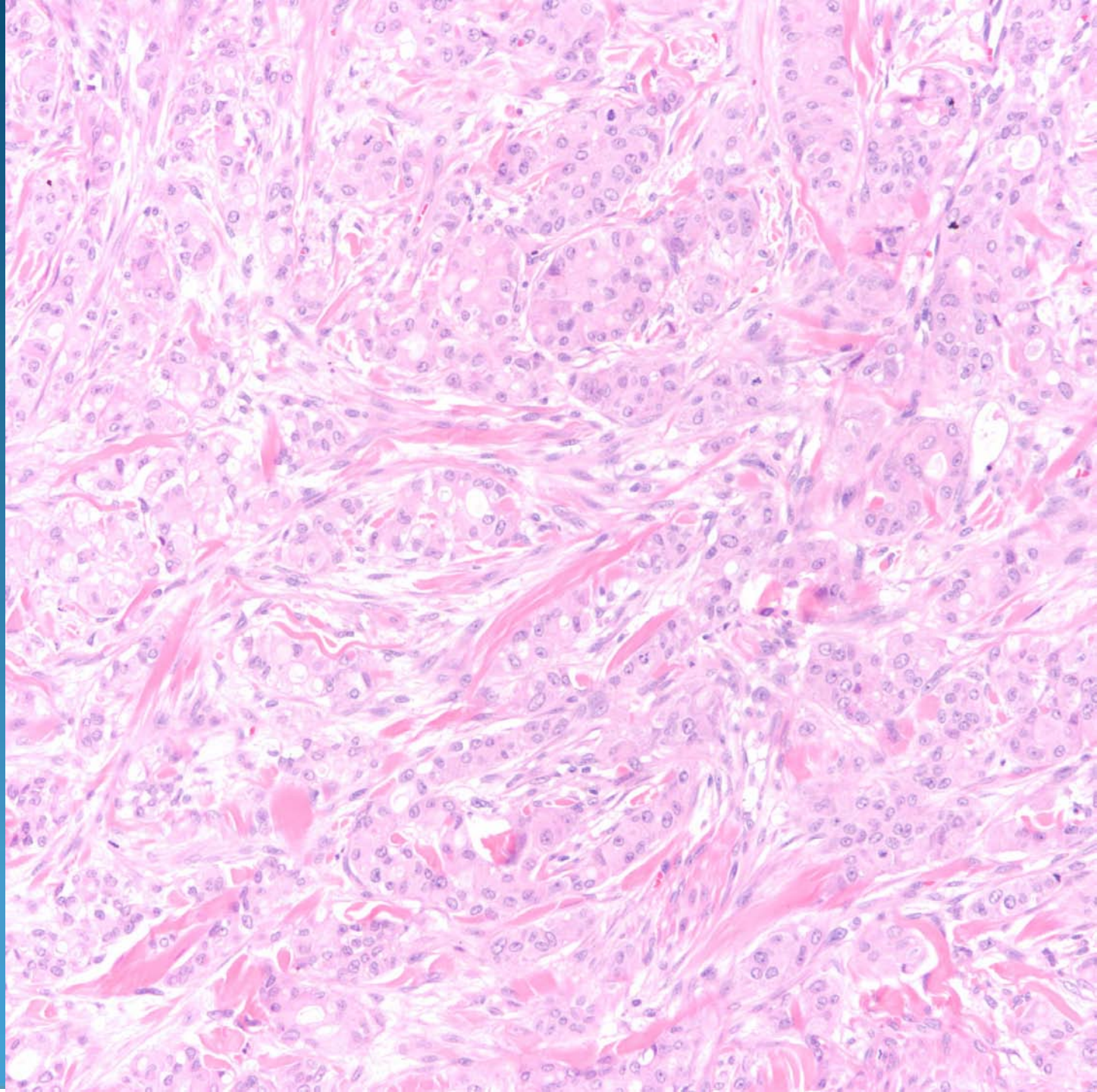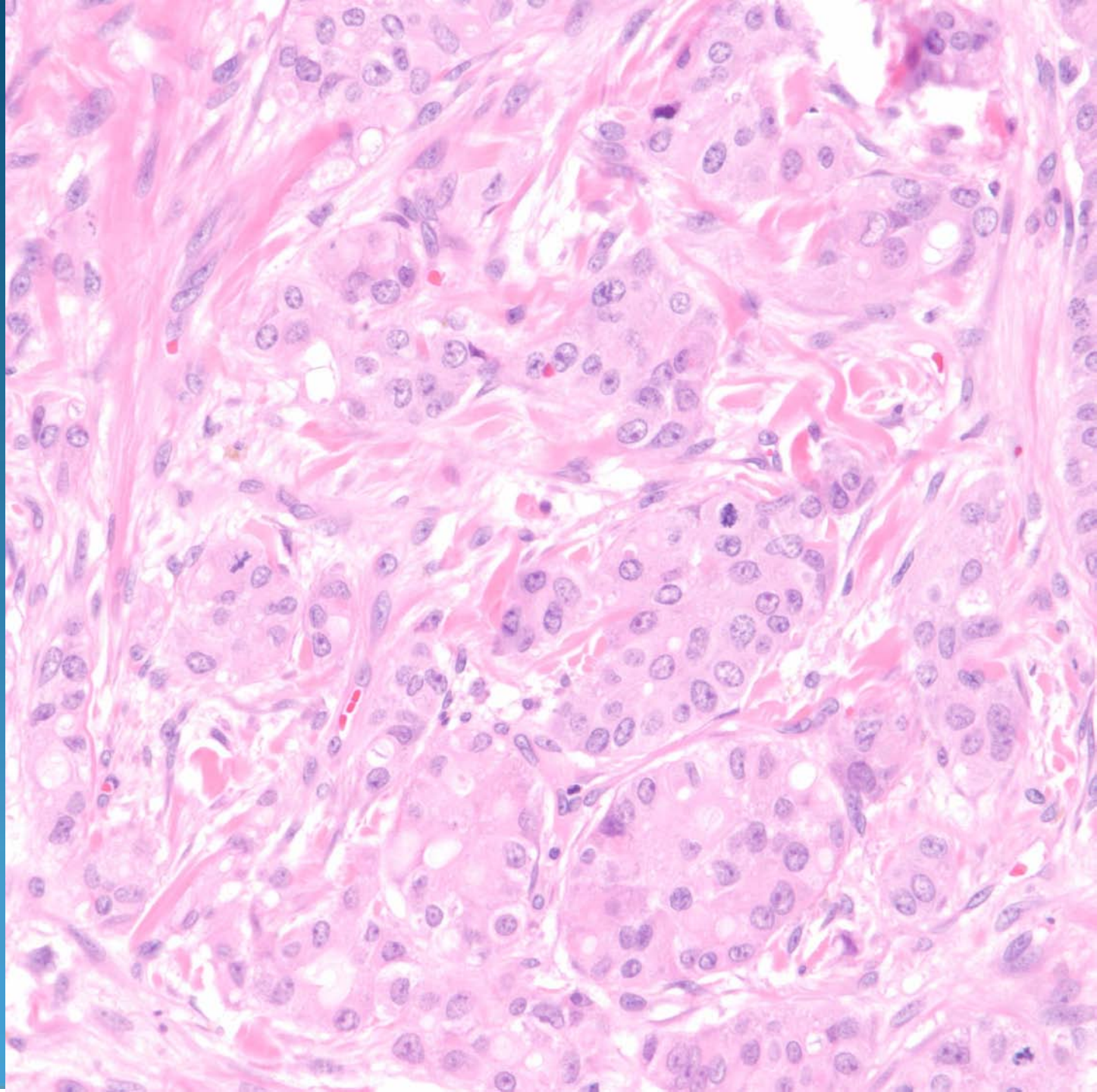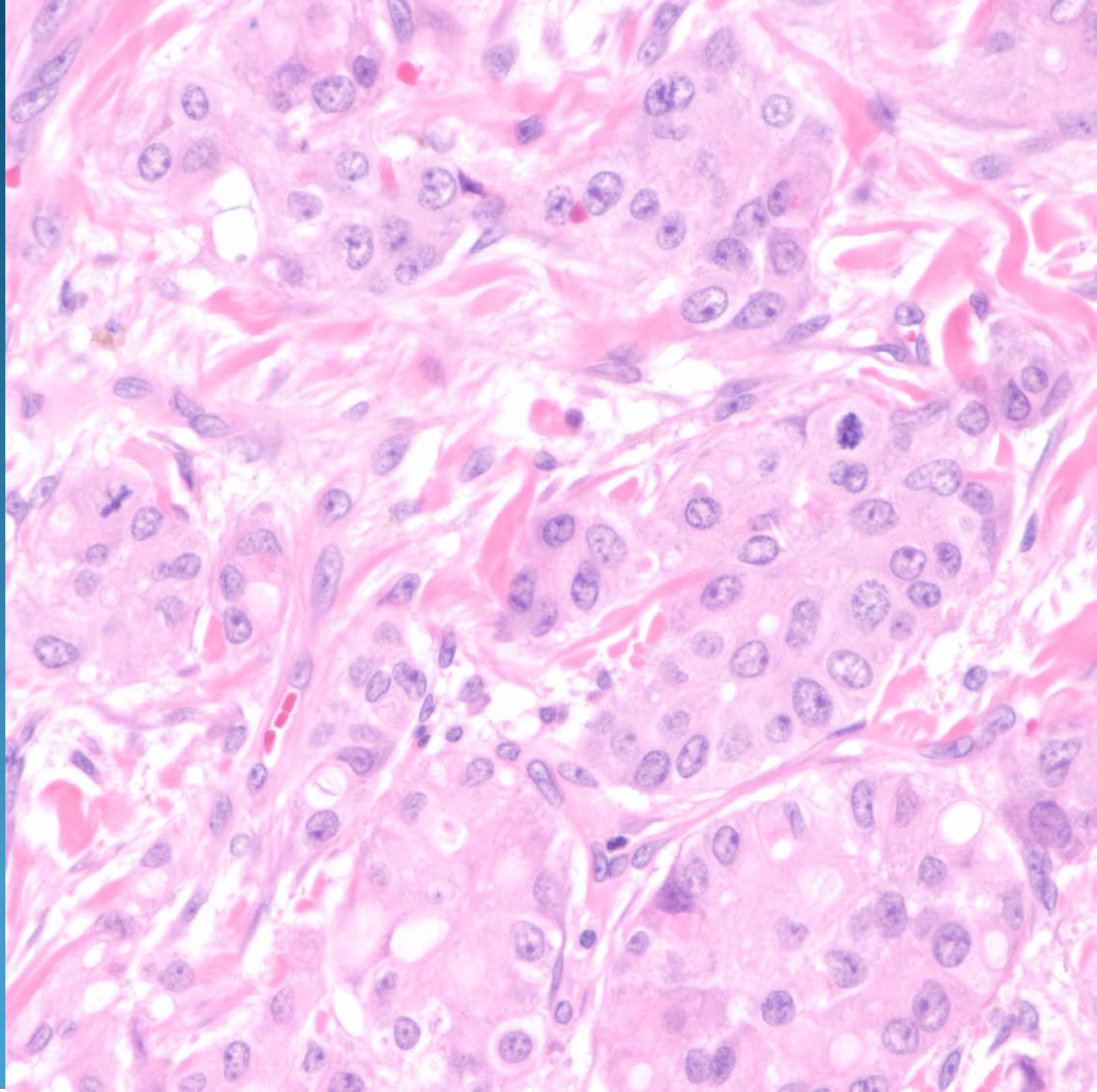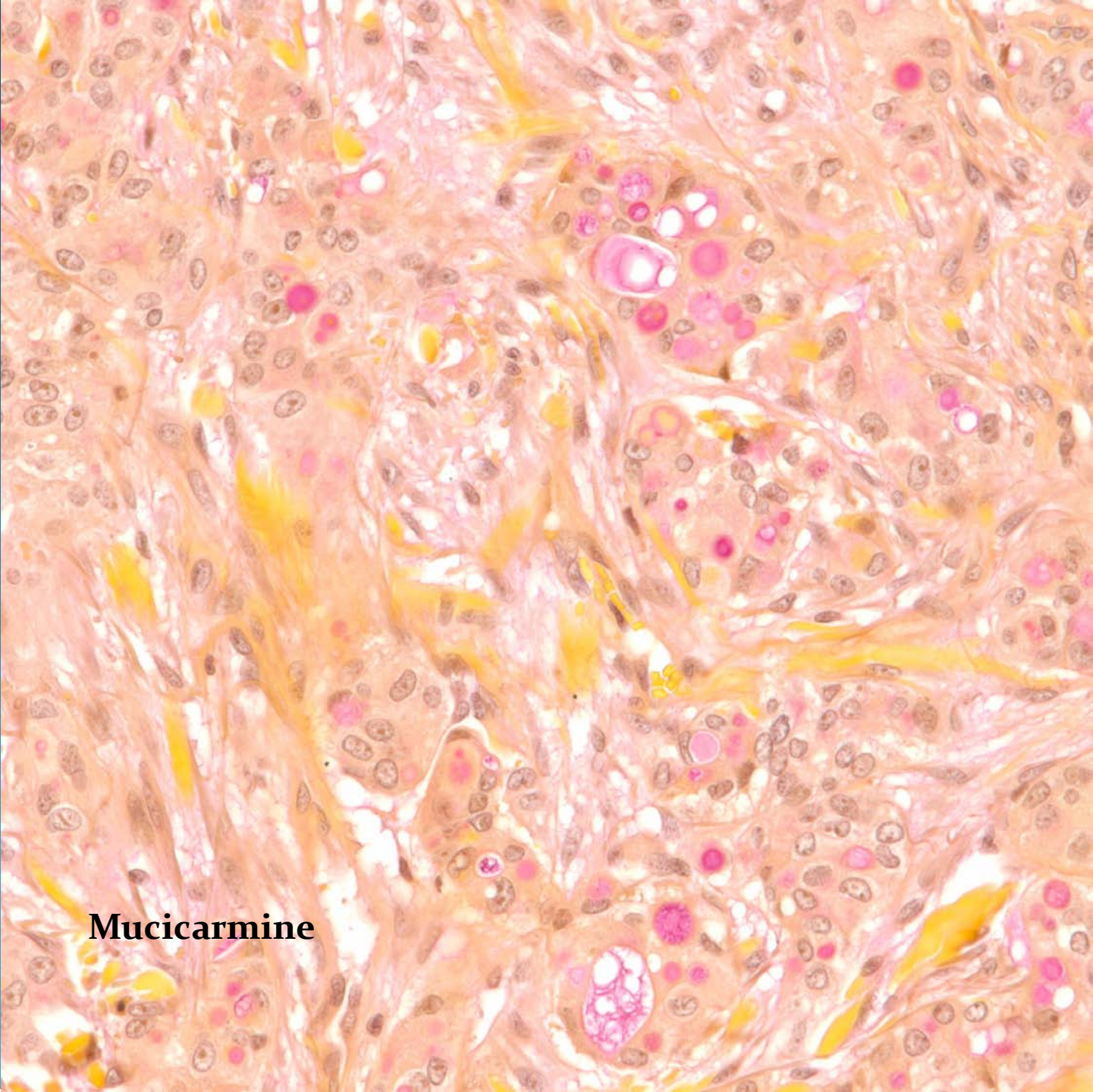
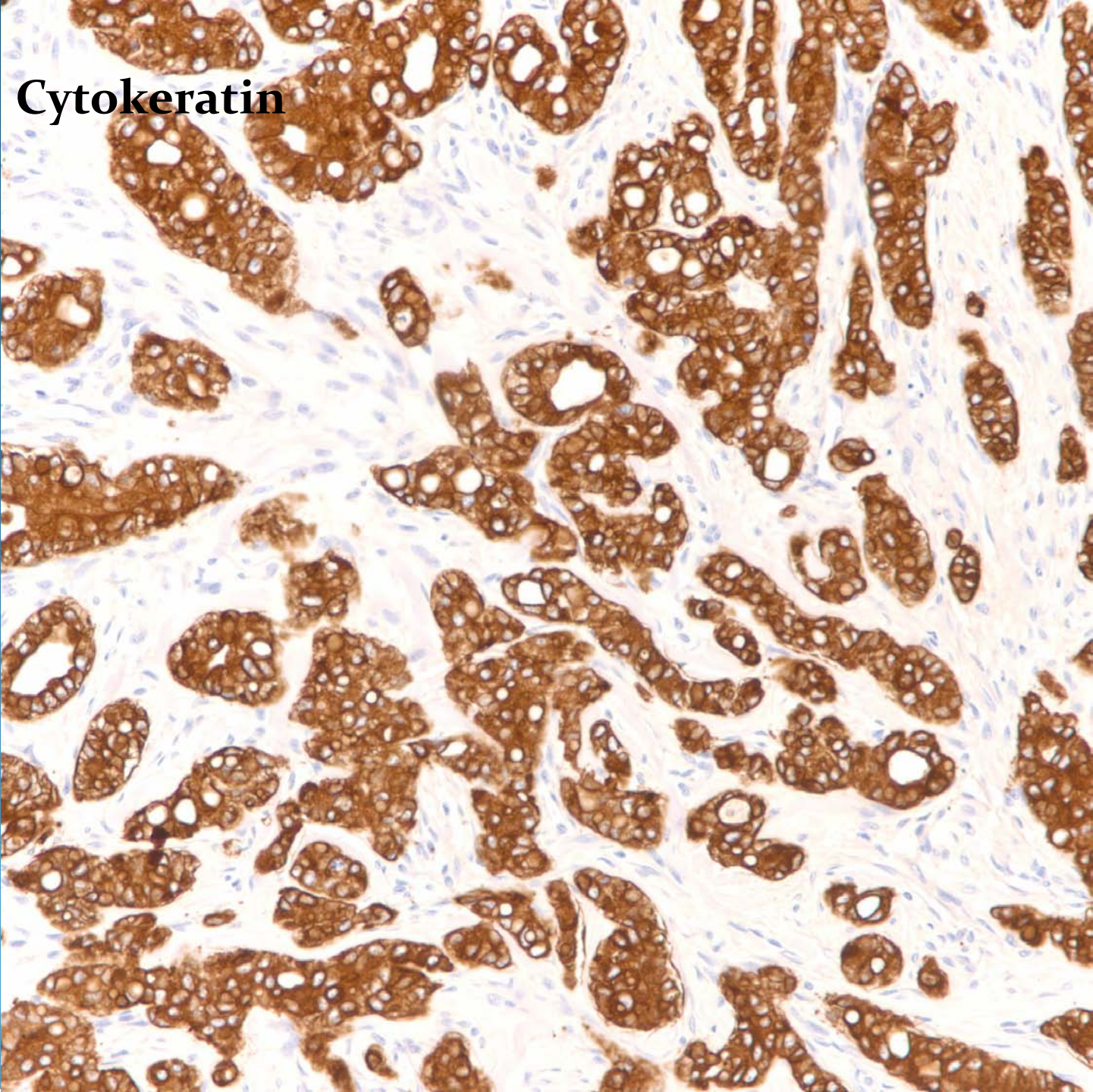


Metastatic Adenocarcinoma to the Skin (Lung Primary)

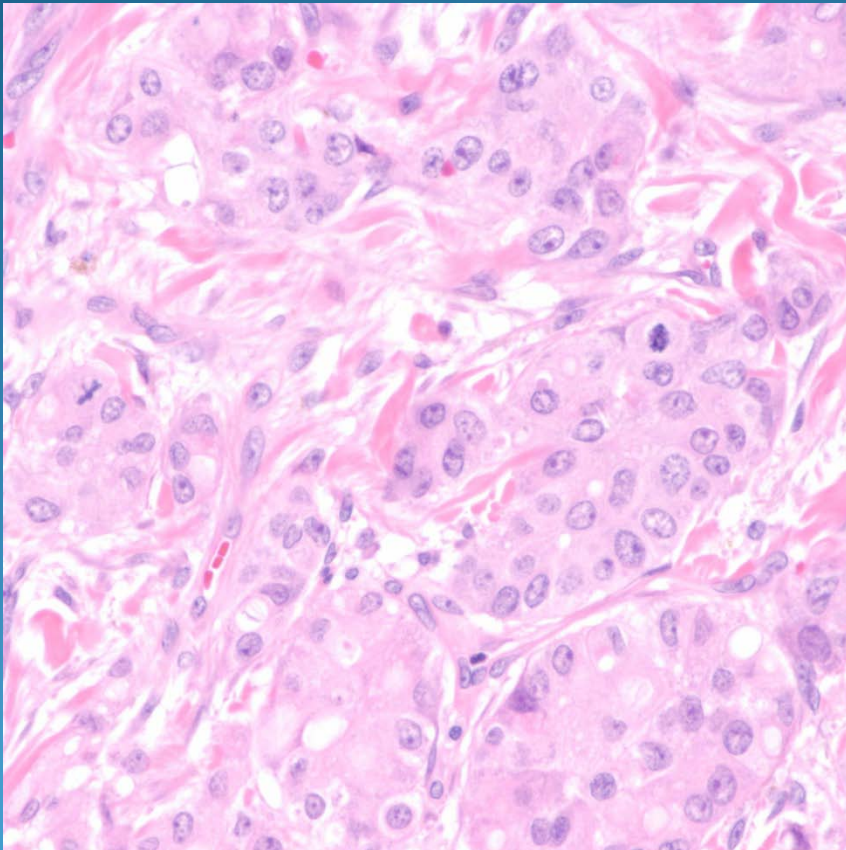


Mucicarmin

Cytokeratin



Pearls



- Adenocarcinoma localized to dermis and variably to subcutaneous fat
- Look for luminal/tubular differentiation
- DDX: Primary eccrine carcinoma
- Confirm with clinical history and immunohistochemistry